



Contents lists available at ScienceDirect

## Foot and Ankle Surgery

journal homepage: [www.journals.elsevier.com/foot-and-ankle-surgery](http://www.journals.elsevier.com/foot-and-ankle-surgery)

# The Akin osteotomy without fixation in open hallux abducto-valgo correction surgery – A single center retrospective analysis of 286 cases

Enrique Adrian Testa<sup>a,b,1</sup>, Annamaria Porreca<sup>c</sup>, Alberto Ruiz Nasarre<sup>d</sup>, Daniel Poggio Cano<sup>e,2</sup>,  
Fernando Alvarez Goenaga<sup>d,3</sup>, Gerardo Ledermann<sup>b,f,4</sup>, Albert Baduell<sup>e,5</sup>,  
Pablo Ruiz Riquelme<sup>b,f,g,\*,6</sup>

<sup>a</sup> Orthopaedic Surgery and Traumatology, Ospedale Regionale Bellinzona, Bellinzona, Switzerland

<sup>b</sup> Master Fellow Foot and Ankle Surgery, University of Barcelona, Barcelona, Spain

<sup>c</sup> Department of Medical, Oral and Biotechnological Sciences, "G. d'Annunzio" University of Chieti-Pescara, 66100 Chieti, Italy

<sup>d</sup> Foot and Ankle Unit, Department of Orthopedic and Traumatology, Hospital Sant Rafael, Barcelona, Spain

<sup>e</sup> Foot and Ankle Unit, Department of Orthopedic and Traumatology, Hospital Clinic, University of Barcelona, Barcelona, Spain

<sup>f</sup> Department of Orthopedic and Traumatology, Hospital Clínico La Florida, 8242238 Santiago, Chile

<sup>g</sup> School of Medicine, Finis Terrae University, 7501015 Santiago, Chile

## ARTICLE INFO

## Article history:

Received 12 November 2022

Received in revised form 11 December 2022

Accepted 2 January 2023

## Keywords:

Akin osteotomy

Proximal phalangeal osteotomy

Closing wedge osteotomy

Hallux valgus

## ABSTRACT

**Background:** Description of a large cohort of Akin osteotomies without fixation (286 feet), to depict the mean angular correction, to analyze complication rates and to pull over with rates described in the literature with other techniques.

**Methods:** Retrospective single-center cohort study. Five radiologic measurements analyzed preoperatively and postoperatively until fusion was completed. Evaluation of all peri- and postoperative complication rates. Evaluation of correlation between complications and the presence of diabetes mellitus (DM), smoking and rheumatic disease.

**Results:** Between 2011 and 2018, 222 patients, 286 feet (147 left, 139 right) met the inclusion criteria. We found an average difference between pre-op and post-op at 3 months of distal articular set angle (DASA) of 7.0 degrees and average interphalangeal joint obliquity angle (IPOA) of 12.0 degrees ( $p < 0.001$ ).

All cases achieved fusion but in 5.9 % (17/289 cases) of cases, we observed delayed consolidation. The average union time in these cases was 22.1 weeks.

Hyperextension of the distal fragment (mal union in plantar flexion) was observed in 7 cases (2.4 %). None of the 7 cases required correction.

Out of 286 surgeries, 8 (2.7 %) required reoperation, but only one case for a hypocorrection required Akin's re osteotomy. Regarding the inter- and intra-observer correlations, good and excellent reliability are observed for all parameters under consideration.

**Conclusion:** The absence of internal fixation would appear not to impair osteotomy healing and complication rates compared with techniques with fixation would not appear to be worse. The results are encouraging; nevertheless, we believe that further studies need to be performed in order to confirm the data.

**Level of evidence:** IV retrospective cases series

© 2023 The Author(s). Published by Elsevier Ltd on behalf of European Foot and Ankle Society. This is an open access article under the CC BY license (<http://creativecommons.org/licenses/by/4.0/>).

\* Correspondence to: Master Fellow Foot and Ankle Surgery, University of Barcelona, Barcelona, Spain Department of Orthopedic and Traumatology, Hospital Clínico La Florida, Santiago de Chile, Chile.

E-mail address: [pabloruiz@gmail.com](mailto:pabloruiz@gmail.com) (P.R. Riquelme).

<sup>1</sup> ORCID: 0000-0001-6153-0011.

<sup>2</sup> ORCID: 0000-0002-7523-9986.

<sup>3</sup> ORCID: 0000-0002-6280-3816.

<sup>4</sup> ORCID: 0000-0002-3944-9599.

<sup>5</sup> ORCID: 0000-0001-8682-1616.

<sup>6</sup> ORCID: 0000-0002-3293-8189.

<https://doi.org/10.1016/j.fas.2023.01.002>

1268-7731/© 2023 The Author(s). Published by Elsevier Ltd on behalf of European Foot and Ankle Society. This is an open access article under the CC BY license (<http://creativecommons.org/licenses/by/4.0/>).

## 1. Introduction

Medial wedge subtractive osteotomy of the proximal phalanx of the first toe was described approximately 100 years ago by Akin to correct the deforming forces of the flexor (FHL) and extensor (EHL) long halluc tendons [1]. This technique has undergone modifications in its fixation once the deformity has been corrected [2–4]. Proposed options include fixation by an interfragmentary screw, single or double staple, K-wires in different positions, plates and transosseous sutures [4–13].

So far, not many data have been presented regarding the possibility of non-fixation of osteotomy, although there has been an increase in publications in recent years, especially regarding minimally invasive techniques [14–16]. The few case series such as Kauffmann's highlight how the non-fixation of Akin's osteotomy in percutaneous technique would seem to maintain the correction and achieve good bone healing [15].

We present a large case series of patients treated for correction of hallux valgus by open surgery in whom an Akin osteotomy was performed without fixation, studying the angular variation between pre- and postoperatively after healing, in cases with follow up to 10 years, performed in a center by a single surgeon.

The objective is a descriptive analysis of postoperative angular changes in the correction considered in the immediate postoperative period and once consolidation is achieved. The second objective is to assess surgery-related complications. Therefore, complication and reoperation rates will also be described.

## 2. Material and methods

Retrospective single-center cohort study, considering patients from a single operator in a single hospital.

We included patients over 18 years old with no previous hallux surgery who have received an Akin osteotomy, from 2011 to 2018, in the context of open hallux abducto-valgus (HAV) correction surgery regardless of the grade and type of metatarsal osteotomy. Patients should have a preoperative clinical and radiographic follow-up and at least two postoperative radiographic follow-ups, the first between 2 and 6 weeks and the second between 8 and 12 weeks and in any case at complete fusion according to the Rush and McClelland studies.[17,18] In case of delayed consolidation, a radiographic course must have been performed until radiographic healing is achieved. Exclusion criteria were patients already operated for HAV or first ray surgery, patients younger than 18 years, patients treated percutaneously, metatarsophalangeal (MTP) fusions, osteotomies of the phalanx other than Akin's, such as Moberg's osteotomy, previous fracture involving the first ray.

### 2.1. Radiographic evaluation and clinical correlations

The 2 angles on which the Akin mainly acts (Fig. 1), namely the distal articular set angle (DASA) and the Inter Phalangeal joint Oblique Angle (IPOA), were measured in the preoperative and then at 2–6 weeks and at 8–12 weeks (and until consolidation occurred). The DASA determines the rapport between the proximal articular plane of the proximal phalanx and the long axis of the proximal phalanx. The IPOA determines the rapport between the proximal articular plane of the proximal phalanx and the distal articular plane of the proximal phalanx (Graph 1 and Graph 2).

The hallux valgus angle (HVA), Inter Metatarsal angle 1–2 (IMA) and Inter Phalangeal angle (IPA) were also measured. The HVA determines the rapport between the long axis of the first metatarsal and the long axis of the proximal phalanx. The IMA 1–2 determines the rapport between the long axis of the first metatarsal and the long axis of the second metatarsal. The IPA determines the rapport

between the long axis of the proximal phalanx and the long axis of the distal phalanx.

The RAIM Viewer v 2.8 digital system (Corporacio Sanitaria Parc Tauli, Parc Tauli 1, Sabadell, Spain) was used for angle measurements. Values were measured to the first decimal degree, rounded up by 1° if values equal or greater than 0.5 degrees and remained unchanged for values less than 0.5 degrees. Radiologic complications including delayed-, non- and mal-union rates were evaluated and recorded. All surgical and postoperative complications were collected. The following data were gathered from all patients: age, presence of DM under pharmacological treatment, rheumatic diseases and smoking. Finally, the intra- and inter-observer correlation rate of two independent researchers of 50 cases on the five parameters previously described in the preoperative was calculated. These measurements were performed twice by the two investigators, four weeks apart from each other. We interpreted the results according to the suggestions of Portney and Koo: "values less than 0.50, between 0.50 and 0.75, between 0.75 and 0.90, and greater than 0.90 are indicative of poor, moderate, good, and excellent reliability, respectively" [19,20].

Patients who had no osteotomy fusion at the second radiographic follow-up (8–12 weeks), were observed clinically and radiologically until consolidation was achieved and the period of union recorded. Delayed union was defined as a period of no fusion greater than 12 weeks and non-union a period of no fusion greater than 36 weeks [17,21,22].

Lateral cortical disruptions during the performance of osteotomy and in radiographic postoperative follow-ups were also recorded. In addition, delayed- and non union, mal union, necrosis, algodystrophy, excessive callus formation, and any other bone changes were evaluated and recorded.

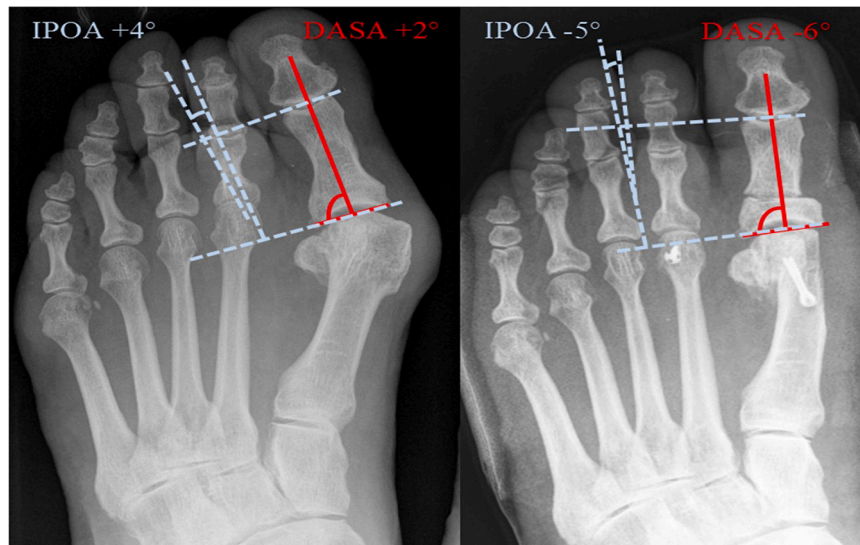
Re interventions were evaluated and all those due to problems related to the proximal phalanx were recorded.

### 2.2. Surgical technique

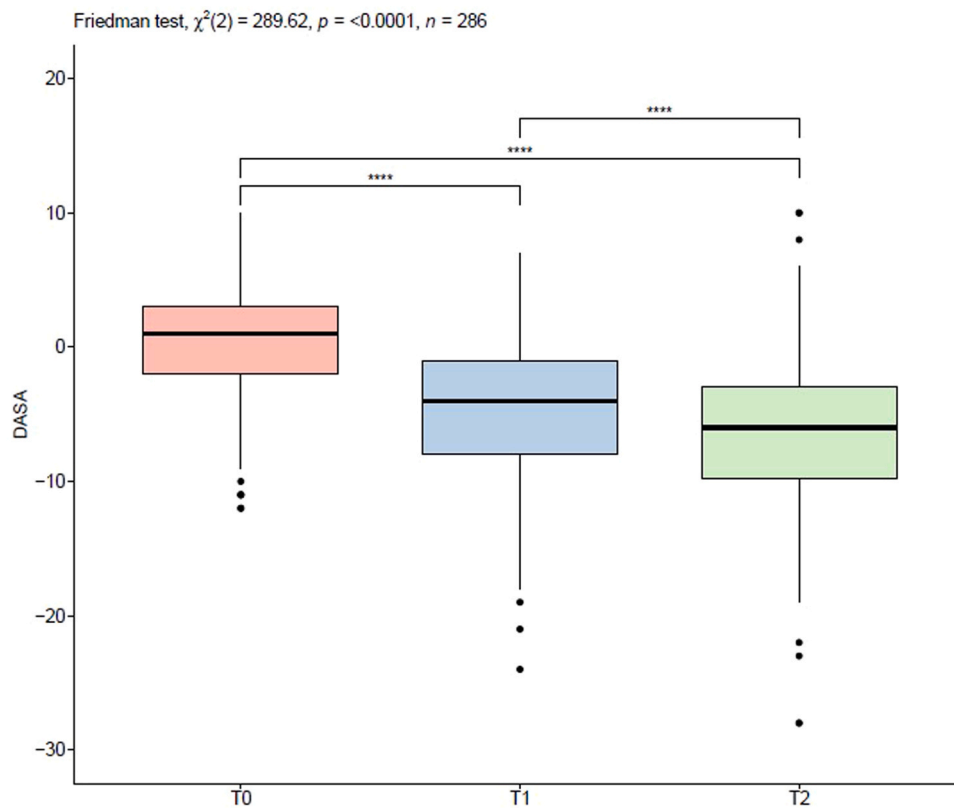
Once the access through a medial approach and surgery on the first metatarsal had been performed, the osteotomy of the phalanx was carried out, carefully preparing the soft tissues, and especially protecting the FHL. At the level of the proximal metaphyseal-diaphyseal transition, normally 8–10 mm from the joint line, a first cut was made parallel to the joint from medial trying to keep the lateral cortical intact. Then a second cut starts about 2–4 mm distal to the previous one in a latero-proximal direction until it had met the first cut trying not to disrupt the lateral cortical. The size of the cut base depends on the desired correction force keeping in mind the calculations of Frey et al. and the clinical aspect after the hallux correction [23]. We usually never exceed 4 mm as the base of the wedge. Once the bone wedge was removed, the gap was closed manually. A medial capsule tension closure was performed, including an X-shaped stitch distally. The bandage consisted of placing 3 elongated gauzes wrapped around the first toe like a tie so that there was variant traction from the bandage as well. One elongated gauze will then be placed in a varus position on each toe. Patches were used on the gauze so that gentle tension was maintained without injuring the skin. (Fig. 2). Immediate full weight-bearing was allowed with the use of rigid sole shoes for the following 4–6 weeks.

### 2.3. Statistical analysis

Descriptive statistics were expressed as median and q1=first quartile, q3=third quartile, for continuous variable and absolute frequency (n) and column percentage (%) for categorical. Normal distribution was verified with the Shapiro-Wilk test, and, for all variables, the null hypothesis of normality was not verified, with a



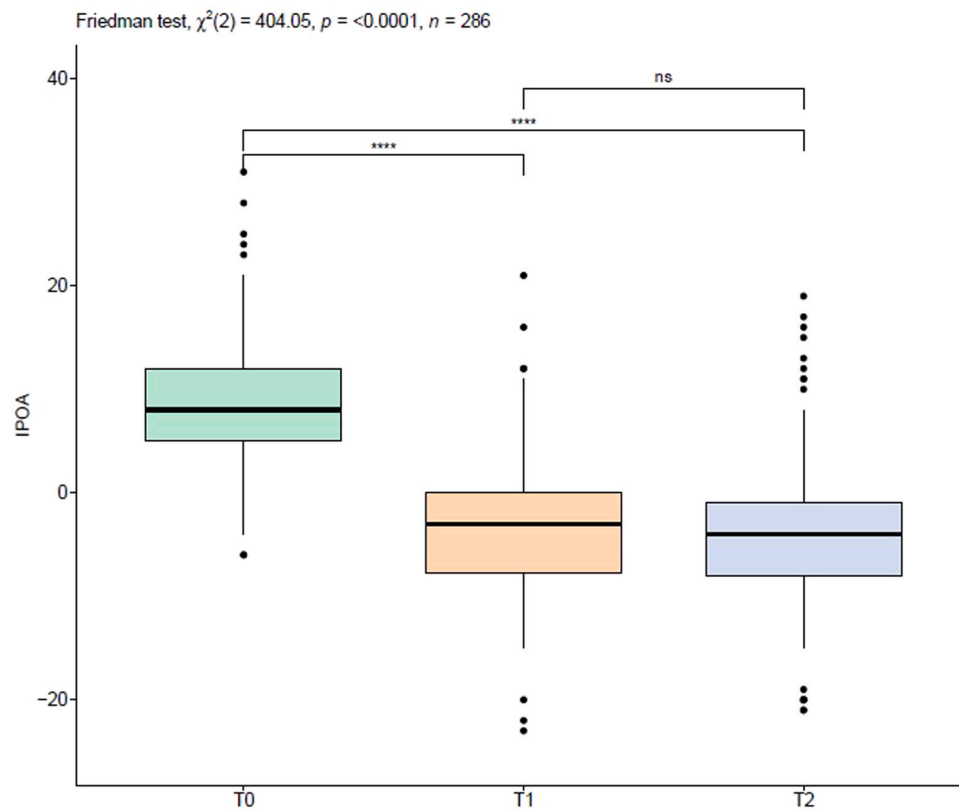
**Fig. 1.** Distal articular set angle (DASA) and interphalangeal joint obliquity angle (IPOA). Preoperative and 6-week postoperative images. In this example, we can observe the corrective power of Akin's osteotomy, noticing a change in DASA (solid lines) of 8 degrees and IPOA (dashed lines) of 9 degrees.



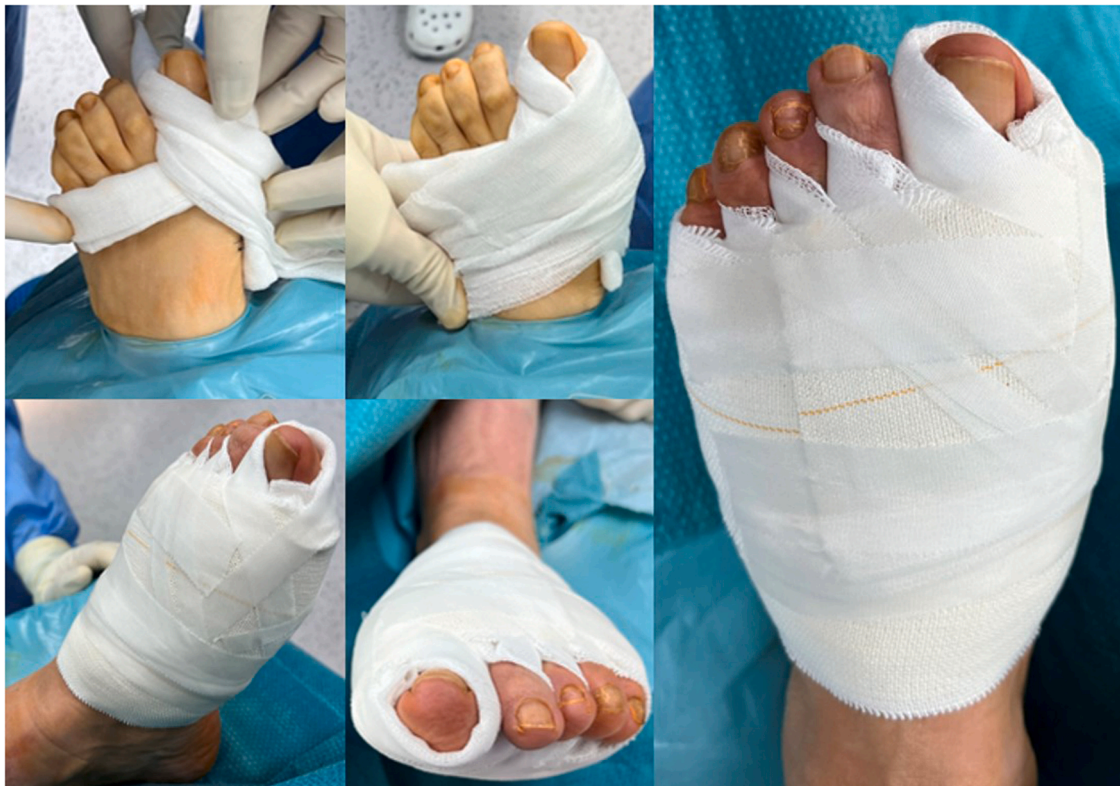**Graph 1.** Boxplot for DASA (Distal articular set Angle) measurements at preoperative time point (T0), at first follow-up (T1) and at complete fusion (T2). Differences over time are assessed by Friedman's test and Dunn's post hoc test, with a Bonferroni correction, which was used to compute multiple pairwise comparisons. Significance codes:  $p < 0.001^{***}$ .

significance level of 95 %. Association between categorical variables was investigated using Pearson's Chi-squared test (for cell frequency  $n \geq 5$ ) and Fisher's exact test (for cell frequency  $n < 5$ ). Friedman test was used to assess differences over time for angle parameters and when the nonparametric analysis of variance resulted in a significant difference between time points, Dunn's post hoc test, with a Bonferroni correction, was used to compute multiple pairwise comparisons. The agreement between readers for the angle variables

(IMA, HVA, DASA, IPA, IPOA) was assessed by Lin's concordance correlation coefficient (CCC). The CCC evaluates the degree to which pairs of observations fall on the 45° line through the origin. It contains a measurement of precision  $\rho$  (the Pearson correlation coefficient, which measures how far each observation deviates from the best-fit line) and accuracy Cb (a bias correction factor that measures how far the best-fit line deviates from the 45° line through the origin):  $\rho c = \rho Cb$ . All statistical tests were 2-sided, with a significance



**Graph 2.** Boxplot for IPOA (Inter Phalangeal Obliquity joint Angle) measurements at a preoperative time point (T0), at first follow-up (T1) and at complete fusion (T2). Differences over time are assessed by Friedman and Dunn's post hoc test, with a Bonferroni correction used to compute multiple pairwise comparisons. Significance codes:  $p < 0.001^{****}$ , ns= not statistically significant.



**Fig. 2.** Bandage sequence. The illustrative sequence shows how we perform the bandage. Three bandages surround the big toe as if to create a "tie" effect that applies a varus force. A single gauze is then passed through each interdigital space in the same direction. Finally, an adhesive patch is applied that gently presses over the head of the first metatarsian toward the lateral, and thin patches are applied to complete the bandage for additional gentle varus force.



level set at  $p < 0.05$ . Analyses were performed using the R software environment for statistical computing and graphics (version 3.4.1; <http://www.r-project.org/>).

#### 2.4. Ethical statement

Permission to perform this study was obtained from the Internal Review Board (Ethics Committee PR-2022-3). This is an observational study; it does not contain any experimental studies with human participants or animals performed by any of the authors.

### 3. Results

Between 2011 and 2018, 523 patients underwent single-operator HAV correction surgery. Of these, 222 patients (196 F, 26 M; mean age 60.5 (20.0, 85.0) years), 286 feet (147 left, 139 right) met the inclusion criteria.

From the extrapolated data, it was observed that 19/222 (8.5 %) patients were diabetics under pharmacological treatment, 17/222 (7.6 %) patients with concomitant rheumatologic diseases, among them rheumatoid arthritis (10), psoriasis (2), systemic lupus erythematosus (2), Sjogren's syndrome (5) and nodular synovitis (1) undergoing cortisone or biologic treatment. The presence of 25/222 (11.2 %) smokers were detected.

#### 3.1. Radiographic results: angular variations

We observed a mean difference between pre-op and at 6 weeks post-op DASA of 5.0 (2.0;8.0) degrees and IPOA of 11.0 (7.0;16.0) degrees ( $p < 0.001$ ). IPA showed an average change of  $-3.0$  ( $-1.0$ ;7.0) degrees ( $p < 0.001$ ). At the same time, the average change in HVA was 26.5 (20.0;32.0) degrees and in IMA was 10.0 (8.0;12.0) degrees ( $p < 0.001$ ).

Comparing data in radiographs at 3 months, we found an average difference between pre-op and post-op of DASA of 7.0 (4.0;10.0) degrees and IPOA of 12.0 (8.0;16.0) degrees ( $p < 0.001$ ). IPA showed a variation of  $-4.0$  ( $-1.0$ ;-8.0) degrees ( $p < 0.001$ ). At the same time, the average change in HVA was 23.5 (18.0;28.0) degrees and in IMA was 8.0 (6.0;10.0) degrees ( $p < 0.001$ ).

Table 1 shows the mean change in the angular parameters considered as a function of time. The mean values are accompanied, in brackets, by values at the first and third quartiles and p values refer to the mean difference between preoperative and postoperative values at first (2–6 weeks) and second (8–12 weeks or at complete fusion) radiological follow up. *Radiographic results: Fusion rates, fusion complications and clinical correlations.*

Table 2 compares the rates of lateral cortical disruption with reference to the rates of delayed union, mal union, excessive callus formation and the three clinical conditions considered. Unintentional lateral cortical disruption was created in 86 cases (30 %). With

**Table 2**

Summary descriptive table by groups of Lateral Cortex Interruption expressed as absolute frequency (n) and column percentage (%).

Variables	Negative Interruption N = 200	Positive Interruption N = 86	p-value
Gender, n (%):			0.701
F	177 (88.5)	74 (86.0)	
M	23 (11.5)	12 (14.0)	
Delayed Union, n (%):			0.017
negative	193 (96.5)	76 (88.4)	
positive	7 (3.5)	10 (11.6)	
Excessive Callus, n (%):			1.000
negative	198 (99.0)	85 (98.8)	
positive	2 (1.00)	1 (1.2)	
Mal Union, n (%):			0.003
negative	199 (99.5)	80 (93.0)	
positive	1 (0.5)	6 (7.0)	

the numbers available, a significant link could be detected ( $p < 0.05$ ) with the first two parameters.

All cases achieved fusion but in 5.9% (17/289 cases) of cases, we observed delayed consolidation. The average union time in these cases was 22.1 (18.5;25.8) weeks. Table 3 compares the rates of delayed union with reference to the rates of lateral cortical disruption, mal union, excessive callus formation and the three clinical conditions considered. With the numbers available, a significant link could be detected ( $p < 0.05$ ) with the first two parameters.

Hyperextension of the distal fragment (malunion in plantar flexion) was observed in 7 cases (2.4%). The data show an average plantar angulation of 7.7 (6.2;9.2) degrees. None of the 7 cases were symptomatic or required correction. Of these 7 cases, 6 had lateral cortical disruption and 4 had delayed union.

#### 3.2. Other post-operative complications

Of 286 surgeries, 8 (2.7 %) required reoperation: one case had an insufficient correction that required a reosteotomy of the metatarsal and phalanx at 1 year, and two cases were surgically reoperated for HAV recurrence (at 3 and 4 years, respectively) without remaking the Akin osteotomy. It should be noted how one of these cases developed algoneurodystrophy (Sudek Syndrome). Excessive bone callus formation was removed in 2 cases. One case had a cheilectomy for hallux rigidus. Finally, 4 cases had superficial wound infection problems of which 2 did not require surgery, while two others had a symptomatic superficial granuloma of the already healed wound that required debridement of the wound itself and without intraoperative signs of deep infection. No cases of deep infection were observed. Table 4 shows all complications related to the surgeries analyzed and all those that required surgical re-intervention.

**Table 1**

Descriptive statistics expressed as median [q1 = first quartil; q3 =third quartil]of the five considered parameters at baseline (T0-preoperative), 1st Follow Up (T1) and when fusion was radiologically verified (T2-Complete Fusion).

Variables	T0 N = 286	T1 N = 286	T2 N = 286	Friedman test p-value	p.T0 vs T1	p.T0 vs T2
IMA [degrees]	13.0 [11.0;15.0]	3.00 [2.00;5.00]	5.00 [4.00;7.00]	< 0.001	< 0.001	< 0.001
HVA [degrees]	33.0 [27.0;38.8]	7.00 [3.00;11.0]	10.0 [5.25;14.8]	< 0.001	< 0.001	< 0.001
DASA [degrees]	1.00 [-2.00;3.00]	-4.00 [-8.00;-1.00]	-6.00 [-9.75;-3.00]	< 0.001	< 0.001	< 0.001
IPA [degrees]	9.00 [4.00;13.0]	12.0 [8.00;15.0]	13.0 [10.0;16.0]	< 0.001	< 0.001	< 0.001
IPOA [degrees]	8.00 [5.00;12.0]	-3.00 [-7.75;0.00]	-4.00 [-8.00;-1.00]	< 0.001	< 0.001	< 0.001

IMA=Intermetatarsal 1–2 Angle, HVA=Hallux Valgus Angle, DASA=Distal Articular Set Angle, IPA=InterPhalangeal angle, IPOA=InterPhalangeal joints Obliquity Angle

**Table 3**

Descriptive statistics for delayed union positivity expressed as absolute frequency (n) and column percentage (%).

Variables	Negative Delay N = 269	Positive Delay N = 17	p-value
Gender, n (%):			0.447
F	237 (88.1)	14 (82.4)	
M	32 (11.9)	3 (17.6%)	
Diabetics, n (%):			0.093
Negative	253 (94.1)	14 (82.4)	
Positive	16 (6.0)	3 (17.6)	
Rheumatics, n (%):			0.267
Negative	254 (94.4)	15 (88.2)	
Positive	15 (5.6)	2 (11.8)	
Smokers, n (%):			0.378
Negative	244 (90.7)	17 (100.0)	
Positive	25 (9.29)	0 (0.0)	
Lateral Cortex Interrupt, n (%):			0.017
Negative	193 (71.7)	7 (41.2)	
Positive	76 (28.3)	10 (58.8)	
Excessive Callus, n (%):			1.000
Negative	266 (98.9)	17 (100.0)	
Positive	3 (1.12)	0 (0.0)	
Mal Union, n (%):			<0.001
Negative	266 (98.9)	13 (76.5)	
Positive	3 (1.1)	4 (23.5)	

**Table 4**

Descriptive statistics expressed as absolute frequency (n) and percentage (%) for complications and the need for reintervention in the sample (N = 286).

Variables	Complications	Need for reintervention
Non Union, n (%):	0 (0.0)	0 (0.0)
Delayed Union, n (%):	17 (5.9)	0 (0.0)
Mal Union, n (%):	7 (2.4)	0 (0.0)
Excessive callus, n (%):	4 (1.4)	2 (0.7)
Recidiva HAV, n (%):	3 (1.0)	3 (1.0)
Deep Infection, n (%):	0 (0.0)	0 (0.0)
Superficial Infection, n (%):	4 (1.4)	2 (0.7)
Algoneurodistrofia, n (%):	1 (0.3)	0 (0.0)
Symptomatic Hallux Rigidus, n (%):	1 (0.3)	1 (0.3)

### 3.3. Inter- and intra-observer correlations

Finally, [Table 5](#) and [Table 6](#) show the inter-observers' concordance in measurement (ICC) and intersession reproducibility for each observer respectively. Reliability between good and excellent is observed for all parameters under consideration.

## 4. Discussion

The data presented in this study describe to our knowledge to date the largest case series of fixation-free Akin osteotomies performed in patients treated for HAV correction with an open technique. The most interesting finding of the present study is the fact that we found no cases of non union.

Recently, the increased use of percutaneous techniques in foot surgery has turned on the discussion regarding whether or not certain types of traditionally osteosynthesized osteotomies should be fixed [14–16]. Akin's osteotomy is no exception, and despite many publications, a gold standard has never been defined [4,6–8,24]. A recent study by Schilde compares classic Akin osteotomy with a percutaneous method but maintains a fixation with synthetic means even in the latter case [16]. The authors discuss the possibility of not fixing the osteotomy but admit that they have no data on this.

**Table 5**

Intraclass Correlation coefficients (ICCs) for the five angular parameters to assess concordance between two independent observers.

Interobserver intrasession reproducibility of measurements			
(Observer 1 vs. Observer 2)	Measure 1 ICC (95 %CI)	Measure 2 ICC (95 %CI)	Mean ICC (95 %CI)
IMA [degrees]	0.842 (0.721–0.910)	0.821 (0.684–0.898)	0.859 (0.752–0.920)
HVA [degrees]	0.956 (0.923–0.975)	0.9485 (0.909–0.971)	0.959 (0.926–0.977)
DASA [degrees]	0.754 (0.567–0.861)	0.685 (0.445–0.821)	0.753 (0.565–0.860)
IPA [degrees]	0.622 (0.335–0.786)	0.738 (0.538–0.851)	0.745 (0.551–0.855)
IPOA [degrees]	0.787 (0.625–0.879)	0.789 (0.628–0.880)	0.818 (0.679–0.897)

IMA = InterMetatarsal Angle; HVA = Hallux Valgus Angle; DASA = Distal Articular Set Angle; IPA = InterPhalangeal Angle; IPOA = InterPhalangeal joints Obliquity Angle

**Table 6**

Lin's Concordance correlation coefficient (CCC) to assess intersession reproducibility for each observer.

(Measure 1 vs. Measure 2)	Observer 1 CCC (95 %CI)	Observer 2 CCC (95 %CI)
IMA [degrees]	0.860 (0.766–0.918)	0.928 (0.879–0.958)
HVA [degrees]	0.987 (0.977–0.992)	0.967 (0.944–0.981)
DASA [degrees]	0.701 (0.554–0.806)	0.762 (0.616–0.857)
IPA [degrees]	0.700 (0.528–0.817)	0.8154 (0.697–0.890)
IPOA [degrees]	0.912 (0.851–0.949)	0.842 (0.739–0.906)

IMA = InterMetatarsal Angle; HVA = Hallux Valgus Angle; DASA = Distal Articular Set Angle; IPA = InterPhalangeal Angle; IPOA = InterPhalangeal joints Obliquity Angle.

### 4.1. Angular variations

Few articles describe the results of radiographic correction after Akin osteotomies. Our results show an average correction of the two main parameters, DASA and IPOA, of 7.0 (4.0;10.0) degrees and 12.0 (8.0;16.0) degrees, respectively. Reliability between good and excellent is observed for all parameters under consideration, demonstrating that DASA and IPOA are parameters that can be accounted for the evaluation of corrective changes such as those considered in this study by having a reproducibility similar to that observed for HVA and IMA.

IPA showed an unexpected negative mean correction of –4.0 (–1.0;–8.0) degrees but with a very wide variability as shown by the standard deviation and having evaluated corrections with a range between –34.0 degrees and 24.0 degrees, thus proving to be a very unreliable value.

Looking at the study by Frey, who reports a correction around 8 degrees with 3 mm base wedges, we can state that our data come considerably closer to that prediction since the osteotomies performed always had a base between 2 and 4 mm [23].

We considered radiographic examinations at the first follow-up (between 2 and 6 weeks). We can see ([Table 1](#)) a variation from the preoperative values that are close to the values at the final control (between 8 and 12 weeks) but we still observe alterations in all parameters. We believe that this finding is due not to a true variation in the correction values but to a projective factor of the images related to two factors: the presence at the first control of the corrective bandage that alters the position of the foot and secondary to the fact that many patients do not load correctly and completely at the first control, often out of fear or an adjustment position of the forefoot, a

factor that regularizes in the following weeks and with the removal of the bandage and the resumption of walking with regular shoes.

#### 4.2. Complications

The advantages of not having to use fixation are obvious: firstly, an economic saving related to not using osteosynthesis material; secondly, a saving of time during the surgical procedure; thirdly, the absence of possible complications such as perforation of the joint in the insertion of material, non-tolerance of the material with no need for its removal, migration of the material or irritation of the tendons by the material itself. In our opinion, only transosseous suture presents fewer risks related to the presence of metal material, although it adds a slight increase in operating time. These aspects make the option of not fixing the osteotomy, a choice to be considered. Our results are encouraging and confirm the trend observed in percutaneous surgery in which fixation is usually not performed following proximal phalanx osteotomy.

#### 4.3. Non union and delayed union

Few articles discuss the possible complications of Akin osteotomy [7,25,26]. Nonunion rates described vary between 0.0 % and 2.2 % [7,23,25,27–29]. Delayed union rates described range between 3.4 % and 28.3 % [15,24,30].

Our data show a non union rate of 0.0 % and a mean delayed union rate of 5.9 % (17/289). All radiographic delayed union cases had no clinical signs and had a positive evolution with a mean fusion of 22.1 weeks. These data are comparable to those of a recent study by Herrera Perez who finds, that in 9 of 26 delayed union cases, complete fusion at 8 months [30]. Of the 16 delayed union cases in our case series, 9 had iatrogenic lateral cortical disruption. Although the numbers should be viewed with caution, we can say that there is a correlation between delayed union rates and lateral cortical disruption. Kauffmann et al., in his series of 81 feet treated percutaneously without Akin fixation, shows that an interruption of the lateral cortical does not correlate with a non-union of the osteotomy [15]. Our data confirm this conclusion, even in the open technique.

In our case series, the presence of diabetes mellitus and/or associated rheumatic diseases would appear to be uncorrelated with delayed union rates, but we believe that analysis of case studies with higher numbers is needed to draw firm conclusions in this area. With the numbers available, we could not detect a correlation between smoking histories and delayed union rates. This is in line with data presented by other authors, but a higher number would be needed to arrive at correct interpretations [7].

#### 4.4. Malunion

For what concerns a union in a vitiated position, rates between 0.0 % and 24.0 % are described [23,24,28,31]. In our case series, we observe hyperextension of the distal fragment in 7 cases (2.4 %). Some authors have pointed out that maintaining the integrity of the lateral cortical can provide greater stability while avoiding the risk of malunion [7,32,33]. Our data can confirm this theory. Lateral cortical disruption was observed in 6 out of 7 of our cases, but we urge taking these data with caution because of the low number presented. It should be noted how in our series, no case required surgical reintervention for this problem since no deviation greater than 10 degrees was seen in the observed cases, and in no case did the patients demonstrate discomfort or functional limitations.

Douthett describes a disruption of the lateral cortical in 47/132 (35.0 %) cases [7]. Schilde comparing a minimally invasive versus an open case series observes a penetration of the lateral cortical in 51.6 % in the minimally invasive group, while only 13.9 % in the open group [16].

In our study, we observed disruption in 86/286 (30.0 %) cases.

#### 4.5. Limitations

The data should be interpreted with caution since this is a retrospective case series with all the limitations and risks of bias related to that methodology. It should also be emphasized that in order to assess correlations with associated diseases, the sample number should be much larger, and that the Pearson product-moment correlation coefficient  $r$  was not calculated due to the low sample size.

Limitations of measurements are given by the fact that in most cases pronation of the phalanges creates an altered position of the radiographic morphology of the proximal phalanx, its diaphysis and the inter phalangeal joint, partially altering the DASA and IPOA. Especially studies like that of Cakmak show how a rotational alteration affects some biplanar angular parameters when evaluated in the context of HAV, and this assumption should also be considered for our measurements [34]. We believe that measurements using tri-dimensional methods could be used to overcome this limitation but with the disadvantage of additional cost and irradiation.

### 5. Conclusions

The absence of internal fixation would appear not to impair osteotomy healing and complication rates compared with techniques with fixation would not appear to be worse.

The advantages of not having to fix the osteotomy are that it saves money and surgical time, there is no need to remove the osteosynthesis material, and there are no complications associated with using the material.

The results are encouraging; nevertheless, we believe that further studies need to be performed in order to confirm our data.

### Funding

The authors declare that no funds, grants, or other support were received during the preparation of this manuscript. This research did not receive any specific grant from funding agencies in the public, commercial, or not-for-profit sectors.

### Ethical approval

Ethical approval for this study was obtained from the Internal Review Board (Ethics Committee PR-2022–3) of the Germanes Hospitalaries, Hospital Sant Rafael, Barcelona.

### Consent to participate

Not applicable. This article does not contain any experimental studies with human participants or animals performed by any of the authors.

### Consent to publish

Not applicable. This article does not contain any experimental studies with human participants or animals performed by any of the authors.

The authors state that for the illustrative radiographs, informed consent was sought for publication of the images in Fig. 1. In addition, consent was also obtained for the anatomical specimen in Fig. 2.

## Authors contributions

All authors contributed to the study conception and design. Material preparation, data collection and analysis were performed by **Enrique Adrian Testa**, **Alberto Ruiz Nasarre**, **Annamaria Porreca** and **Pablo Ruiz Riquelme**. The first draft of the manuscript was written by Enrique Adrian Testa and all authors commented on previous versions of the manuscript. All authors read and approved the final manuscript.

## Data availability

No further data or material were provided.

## Competing interests

The authors have no relevant financial or non-financial interests to disclose.

## References

- [1] Akin O. The treatment of hallux valgus: a new operative procedure and its results. *Med Sentin* 1925;33:678–9.
- [2] Bonk J H. Chapter 8. Phalangeal Osteotomy for Hallux Valgus. In: Hetherington, V. ed. *Hallux Valgus and Forefoot Surgery*, Medicine, 1994,137–146.
- [3] Brahms MA. Hallux valgus — the Akin procedure. *Clin Orthop Relat Res* 1981;157:47–9. <https://doi.org/10.1097/00003086-198106000-00010>
- [4] Chacon Y, Fallat LM, Dau N, Bir C. Biomechanical comparison of internal fixation techniques for the Akin osteotomy of the proximal phalanx. *J Foot Ankle Surg* 2012;51(5):561–5. <https://doi.org/10.1053/j.jfas.2012.05.001>
- [5] Barouk LS, Barouk P, Baudet B, Toullec E. The great toe proximal phalanx osteotomy: the final step of the bunionectomy. *Foot Ankle Clin* 2005;10(1):141–55. <https://doi.org/10.1016/j.fcl.2004.09.006>
- [6] Cullen NP, Angel J, Singh D, Burg A, Dudkiewicz I. Fixation of an Akin osteotomy with a tension suture: our results. *Foot* 2009;19(2):107–9. <https://doi.org/10.1016/j.foot.2009.01.009>
- [7] Douthett SM, Plaskey NK, Fallat LM, Kish J. Retrospective analysis of the akin osteotomy. *J Foot Ankle Surg* 2018;57(1):38–43. <https://doi.org/10.1053/j.jfas.2017.06.026>
- [8] Liszka H, Gadek A. Comparison of the type of fixation of Akin osteotomy. *Foot Ankle Int* 2019;40(4):390–7. <https://doi.org/10.1177/1071100718816052>
- [9] Mitchell LA, Baxter DE. A chevron — Akin double osteotomy for correction of hallux valgus. *Foot Ankle Int* 1991;12(1):7–14. <https://doi.org/10.1177/107110079101200102>
- [10] Roy SP, Tan KJ. A modified suture technique for fixation of the Akin osteotomy. *J Foot Ankle Surg* 2013;52(2):276–8. <https://doi.org/10.1053/j.jfas.2012.11.010>
- [11] Schlefman BS. Akin osteotomy with horizontal interosseous wire-loop fixation. *J Am Podiatr Med Assoc* 1999;89(4):194–8. <https://doi.org/10.7547/87507315-89-4-194>
- [12] Sinnett T, Fang Y, Nattfogel E, O'Gorman A, Charalambides C. Suture fixation of an Akin osteotomy: a cost effective and clinically reliable technique. *Foot Ankle Surg* 2017;23(1):40–3. <https://doi.org/10.1016/j.fas.2016.02.002>
- [13] Tóth K, Kellermann P, Wellinger K. Fixation of Akin osteotomy for hallux abductus with absorbable suture. *Arch Orthop Trauma Surg* 2010;130(10):1257–61. <https://doi.org/10.1007/s00402-009-1024-4>
- [14] De Prado M, Ripoll PL, Golanó P. Minimally invasive foot surgery. Barcelona: AYH; 2009.
- [15] Kaufmann G, Handle M, Liebensteiner M, Braito M, Dammerer D. Percutaneous minimally invasive Akin osteotomy in hallux valgus interphalangeus: a case series. *Int Orthop* 2018;42(1):117–24. <https://doi.org/10.1007/s00264-017-3638-4>
- [16] Schilde S, Delank KS, Arbab D, Gutteck N. Minimally invasive vs open Akin osteotomy. *Foot Ankle Int* 2021;42(3):278–86. <https://doi.org/10.1177/1071100720962411>
- [17] McClelland D, Thomas PB, Bancroft G, Moorcraft CI. Fracture healing assessment comparing stiffness measurements using radiographs. *Clin Orthop Relat Res* 2007;457:214–9. <https://doi.org/10.1097/BLO.0b013e31802f80a8>
- [18] Rush SM, Hamilton GA, Ackerson LM. Mesenchymal stem cell allograft in revision foot and ankle surgery: a clinical and radiographic analysis. *J Foot Ankle Surg* 2009;48:163–9. <https://doi.org/10.1053/j.jfas.2008.12.008>
- [19] Koo Terry K, Mae YLi. A guideline of selecting and reporting intraclass correlation coefficients for reliability research. *J Chiropr Med* 2016;15(2):155–63. <https://doi.org/10.1016/j.jcm.2016.02.012>
- [20] Portney LG, Watkins MP. *Foundations of clinical research: applications to practice*. New Jersey: Prentice Hall; 2000.
- [21] Mahan KT. Chap 17 management of delayed unions and nonunions. In: Camasta CA, Vickers NS, Carter SR, editors. *Reconstructive surgery of the foot and leg: update '95*. Tucker, GA: Podiatry Institute; 1995. p. 94–7.
- [22] Rozbruch Pugh. Chap 13 non unions and malunions. In: Baumgartner MR, Tornetta P, editors. *Orthopaedic knowledge update*. Trauma 3 Orthopaedic Trauma Association; 2011. p. 115–30.
- [23] Frey C, Jahss M, Kummer FJ. The Akin procedure: an analysis of results. *Foot Ankle Int* 1991;12:1–6. <https://doi.org/10.1177/107110079101200101>
- [24] Montiel V, Suárez Á, Riera L, Villas C, Alfonso M. Akin osteotomy: is the type of staple fixation relevant? *Int Orthop* 2020;44(7):1435–9. <https://doi.org/10.1007/s00264-020-04563-4>
- [25] Makwana NK. Osteotomy of the hallux proximal phalanx. *Foot Ankle Clin* 2001;6:455–71. [https://doi.org/10.1016/s1083-7515\(03\)00107-4](https://doi.org/10.1016/s1083-7515(03)00107-4)
- [26] Roukis TS. Hallux proximal phalanx Akin-Scarfe osteotomy. *J Am Podiatr Med Assoc* 2004;94(1):70–2. <https://doi.org/10.7547/87507315-94-1-70>
- [27] Goldberg I, Bahar A, Yosipovitch Z. Late results after correction of hallux valgus deformity by basilar phalangeal osteotomy. *J Bone Jt Surg Am* 1987;69:64–7.
- [28] Green AH, Bosta SD. Akin osteotomy of the hallux proximal phalanx utilizing Richards's mini staple fixation. *J Foot Surg* 1986;25:386–9.
- [29] Seelenfreund M, Fried A. Correction of hallux valgus deformity by basal phalanx osteotomy of the big toe. *J Bone Jt Surg Am* 1973;55:1411.
- [30] Herrera-Perez M, De Prado-Serrano M, Gutiérrez-Morales MJ, Boluda-Mengod J, Pais-Brito JL. Increased rates of delayed union after percutaneous Akin osteotomy. *Foot Ankle Surg* 2018;24(5):411–6. <https://doi.org/10.1016/j.fas.2017.04.010>
- [31] Donahue WE, Donahue Jr WE. The proximal phalangeal osteotomy: a technically advanced approach. *Clin Podiatry* 1985;2:449–55.
- [32] Christensen JC, Gusman DN, Tencer AF. Stiffness of screw fixation and role of cortical hinge in the first metatarsal base osteotomy. *J Am Podiatr Med Assoc* 1995;85:73–82. <https://doi.org/10.7547/87507315-85-2-73>
- [33] Goldner JL, Gaines RW. Adult and juvenile hallux valgus: analysis and treatment. *Orthop Clin North Am* 1976;7:863–87.
- [34] Cakmak G, Kanatlı U, Kılınc B, Yetkin H. The effect of pronation and inclination on the measurement of the hallux distal metatarsal articular set angle. *Acta Orthop Trauma Turc* 2013;47(5):354–8. <https://doi.org/10.3944/aott.2013.2669>